

The Heart of Companion Care
www.cvcavets.com
 1209 Cromwell Bridge Road
 Towson MD 21286
 Phone: 410-828-0911 Fax: 410-828-1074

Medical Record

| | | |
|--|------------------------|-----------------------|
| Client: Pritchard, Smooth Operator | Patient number: 146063 | Exam date: 01/15/2011 |
| Patient name: Smooth Operator | Species: Feline | Breed: Cornish Rex |
| Phone: | Sex: M | Age: 3 years |
| Weight: 6.5 lbs oz = 2.9 kg | | |
| Examining Veterinarian: Steven Rosenthal, DVM, DACVIM (Cardiology) and William Tyrrell, DVM, DACVIM (Cardiology) | | |

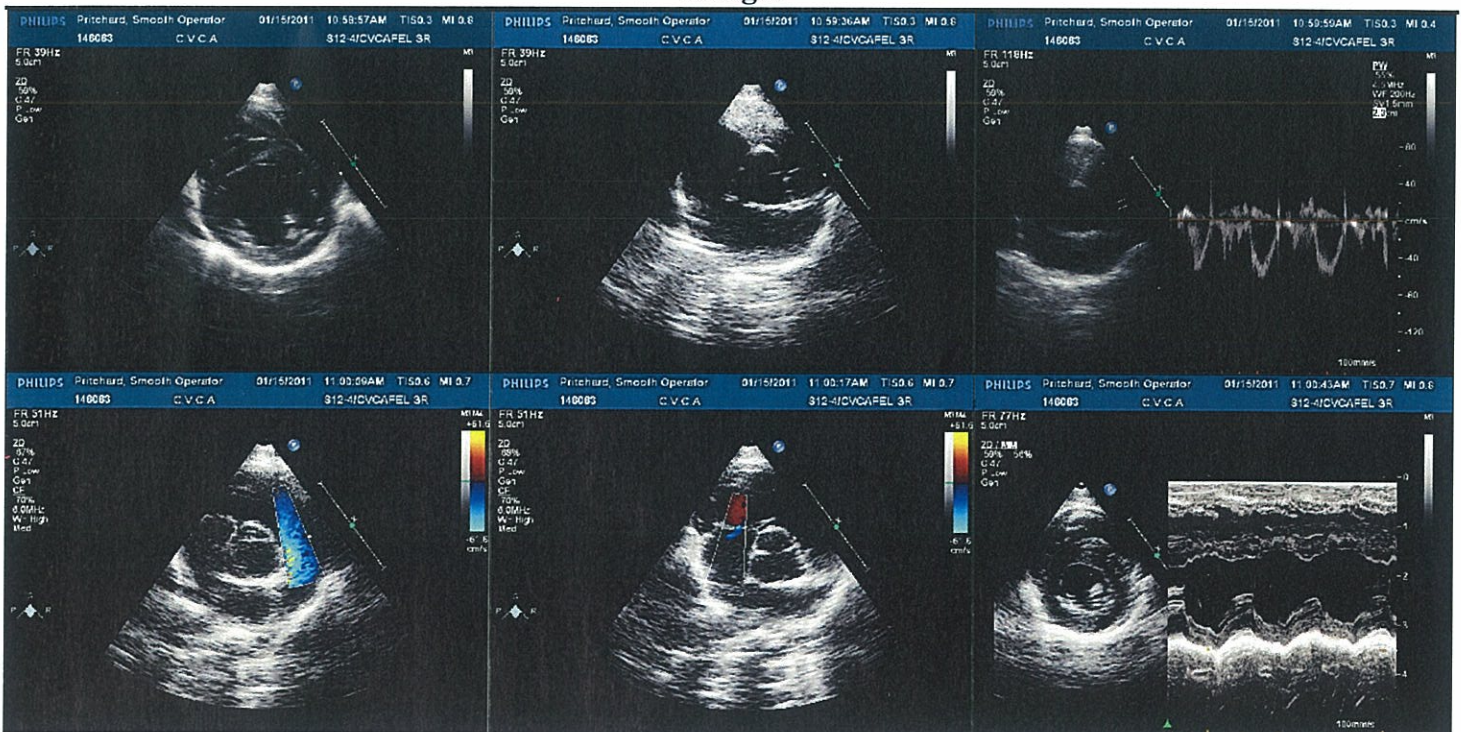
Diagnosis

No signs of cardiomyopathy
 Normal echocardiogram

Recommendations

- Medications:** No cardiac are medications recommended at this time
- Please note:** No specific precautions noted for continuation in a breeding program
- Reevaluation:** Continue routine care with your primary care veterinarian
 Follow up with CVCA if changes are noted during routine examinations, clinical symptoms occur or every few years if continued use in the breeding program

Images





Patient Name: Pritchard, Smooth Operator

Patient ID: 146063

Exam Date: 01/15/2011

Electronically signed by Steven Rosenthal, DVM, DACVIM (Cardiology) and William Tyrrell, DVM, DACVIM (Cardiology) 1/15/2011 11:04 AM

Visit Summary:

Heart Rate: 180 bpm

Blood Pressure: mmHg

History: Presented for Evaluation in HCM Clinic

Physical Exam Findings: Grade I/VI systolic murmur over the left base, arrhythmias or gallops, strong pulses, normal color and refill time, normal respiratory, clear lung sounds, ABD-NSF

Echocardiographic Findings

Echo: Normal wall thickness, High normal left ventricular chamber dimensions, normal left ventricular systolic function, normal mitral valve motion, normal color flow Doppler studies of the left and right ventricular outflow tracts, no effusions or masses, trace tricuspid valve regurgitation, no signs of or predictors for cardiomyopathy, single moderator band

Comments

Fortunately, there are no signs of hypertrophic cardiomyopathy in this feline patient today. It appears that we can continue the use of this cat in a breeding program. We recommend twice yearly examinations with your primary care veterinarian for all cats of breeds that are of risk for cardiomyopathy. Signs of hypertrophic cardiomyopathy can develop at any age.

Thank you for visiting us at this clinic setting today.

Steven Rosenthal, DVM, DACVIM (Cardiology)

William Tyrrell, DVM, DACVIM (Cardiology)

Measurements:

| 2D Measurements | |
|-----------------------------------|----------------------|
| LA Area | 1.87 cm ² |
| RVIDd | 0.44 cm |
| LA Dimension | 1.00 cm |
| A _o Root Diam | 1.0 cm |
| LA Dim : A _o Root Diam | 1.00 |
| IVSd | 0.27 cm |
| LVIDd | 1.74 cm |
| LVPWd | 0.35 cm |
| IVSd/LVPWd | 0.771 |

| Doppler Measurements: | |
|-------------------------|-----------|
| RV Outflow Tract | |
| RVOT Velocity | 0.6 m/s |
| RVOT PG | 1.40 mmHg |

| M-Mode Measurements | |
|-----------------------------------|---------|
| IVSd | 0.28 cm |
| RVIDd | 0.6 cm |
| LVIDd | 1.61 cm |
| LVPWd | 0.29 cm |
| IVSd/LVPWd | 0.965 |
| IVSs | 0.55 cm |
| LVIDs | 0.83 cm |
| LVPWs | 0.58 cm |
| % FS | 48.4 % |
| LA Dimension | 1.20 cm |
| A _o Root Diam | 0.90 cm |
| LA Dim : A _o Root Diam | 1.33 |
| EDV | 7.29 ml |
| ESV | 1.22 ml |
| SV | 6.1 ml |
| % EF | 83.2 % |
| LVPW% | 96.90 % |