

The Heart of Companion Care
www.cvcavets.com
 1209 Cromwell Bridge Road
 Towson MD 21286
 Phone: 410-339-3461 Fax: 410-828-5315

Medical Record

Client: Pritchard, Kaylee's Cinderella	Patient number: 2511ay	Exam date: 05/14/2011
Patient name: Kaylee's Cinderella	Species: Feline	Breed: Cornish Rex
Phone:	Sex: F	Age: 9 months
Weight: 4.5 lbs oz = kg		
Examining Veterinarian: Steven Rosenthal, DVM, DACVIM (Cardiology), William Tyrrell, DVM, DACVIM (Cardiology)		

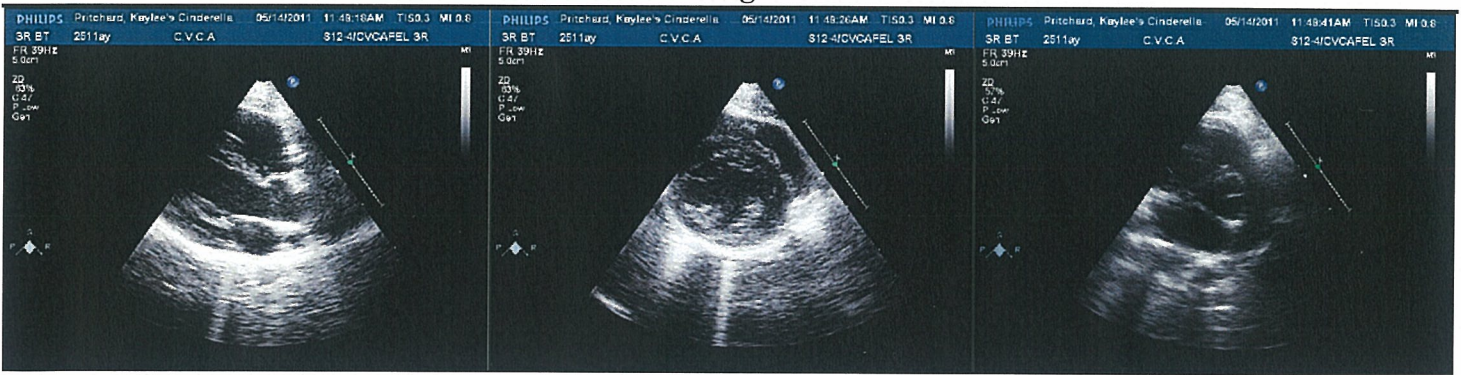
Diagnosis

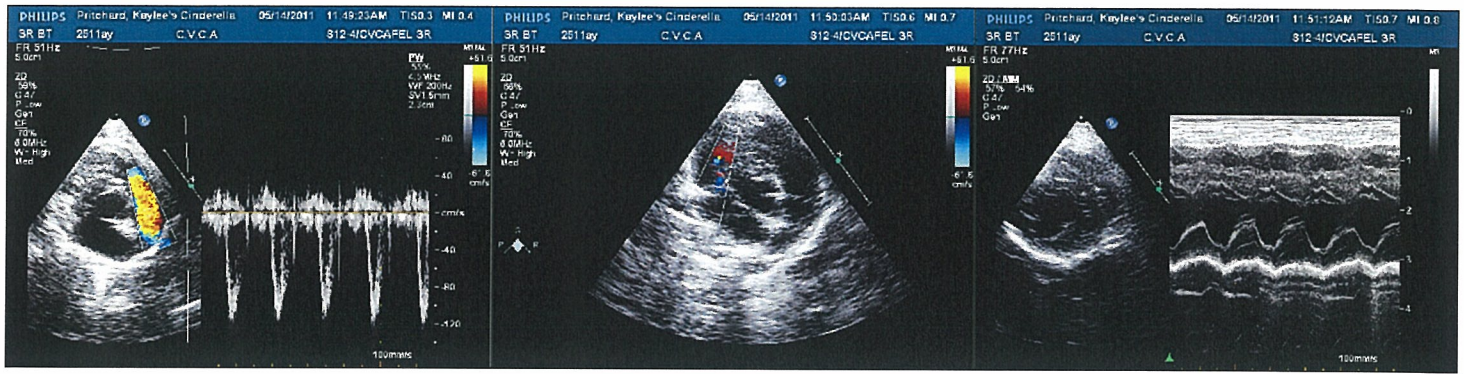
No signs of cardiomyopathy
 Normal echocardiogram

Recommendations

- Medications:** No medications recommended at this time
 No specific precautions noted for continuation in a breeding program.
- Reevaluation:** Continue routine care with your primary care veterinarian
 Follow up with CVCA to recheck the echocardiogram if changes are noted during routine physical exams, clinical symptoms occur or every few years if continuing in the breeding program.

Images





Electronically signed by Steven Rosenthal, DVM, DACVIM (Cardiology), William Tyrrell, DVM, DACVIM (Cardiology) 5/14/2011 11:56 AM

Visit Summary:

Heart Rate: 210 bpm

Blood Pressure: mmHg

History: Presented for Evaluation in HCM Clinic

Physical Exam Findings: Auscultation findings within normal limits, no ausculted murmurs arrhythmias or gallops, strong pulses, normal color and refill time, normal respiratory, clear lung sounds, ABD-NSF

Echocardiographic Findings

Echo: Normal wall thickness, normal chamber dimensions, normal left ventricular systolic function, normal mitral valve motion, normal color flow Doppler studies of the left and right ventricular outflow tracts, LV moderator bands, no effusions or masses, mild tricuspid valve regurgitation, no signs of or predictors for cardiomyopathy.

Comments

Fortunately, there are no signs of hypertrophic cardiomyopathy in this feline patient today. It appears that we can continue the use of this cat in a breeding program. We recommend twice yearly examinations with your primary care veterinarian for all cats of breeds that are of risk for cardiomyopathy. Signs of hypertrophic cardiomyopathy can develop at any age. Thank you for visiting us at this clinic setting today.

Steven Rosenthal, DVM, DACVIM (Cardiology)

William Tyrrell, DVM, DACVIM (Cardiology)

Measurements:

2D Measurements	
LA Area	1.36 cm ²
LA Dimension	0.90 cm
A ₀ Root Diam	0.9 cm
LA Dim : A ₀ Root Diam	1.00
IVSd	0.27 cm
LVIDd	1.10 cm
LVPWd	0.37 cm
IVSd/LVPWd	0.729

Doppler Measurements:	
RV Outflow Tract	
RVOT Velocity	1.2 m/s
RVOT PG	5.80 mmHg

M-Mode Measurements	
IVSd	0.37 cm
LVIDd	1.33 cm
LVPWd	0.40 cm
IVSd/LVPWd	0.925
IVSs	0.45 cm
LVIDs	0.49 cm
LVPWs	0.73 cm
% FS	63.1 %
LA Dimension	0.80 cm
A ₀ Root Diam	0.80 cm
LA Dim : A ₀ Root Diam	1.00
EDV	4.42 ml
ESV	0.29 ml
SV	4.1 ml
% EF	93.4 %
MV D-E Slope	190.60 cm/s
MV E-F Slope	8.70 cm/s
LVPW%	83.20 %